

DETAILS OF THE INNOVATIONS MADE IN MIDSR DENTAL COLLEGE, LATUR

A) Innovative Models

1) Dental Council of India Model

Submitted by- Anam Momin, Sonali Deldame (Pedodontics department in 2015)



Dental Council of India Model

2) Rain Water Harvesting Model

Submitted by Bhumika J, Suyash Joshi, Suhas K, Mineet K. (Public Health Dentistry department in 2016)



Rain Water Harvesting Model

3) Tooth Plaster model

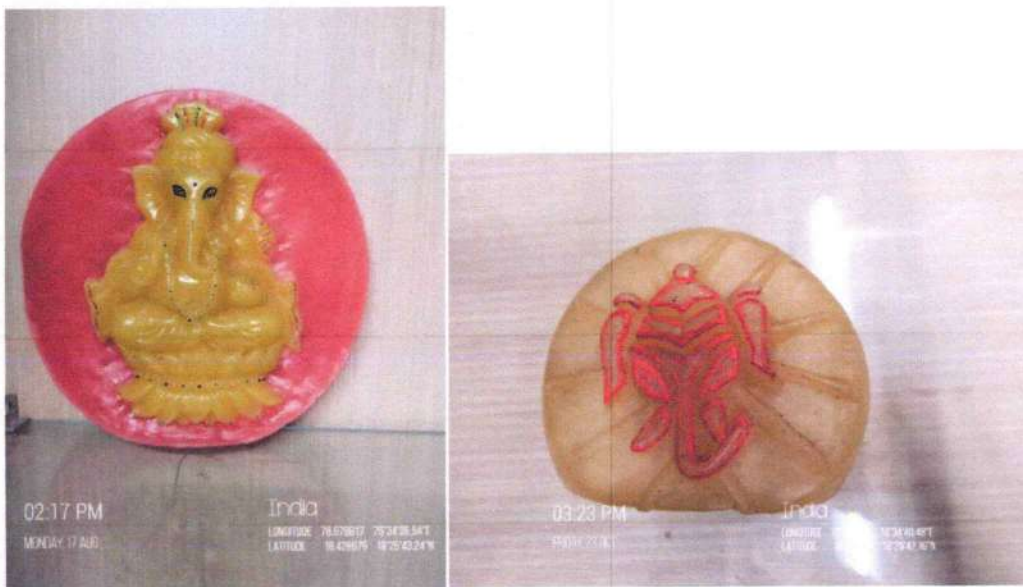
Submitted by Sarika Buddepatil, Prachi Choudhary, Sarika Dhamale. (Public Health Dentistry department in 2018)



Tooth Plaster model

4) Ganpati Wax Model

Submitted by Rohini Goswami, Pavan Shinde, Pallavi, Vishakha Vhote (Oral Pathology department in 2018)



Ganpati Wax Model

5) Microscope Wax Model

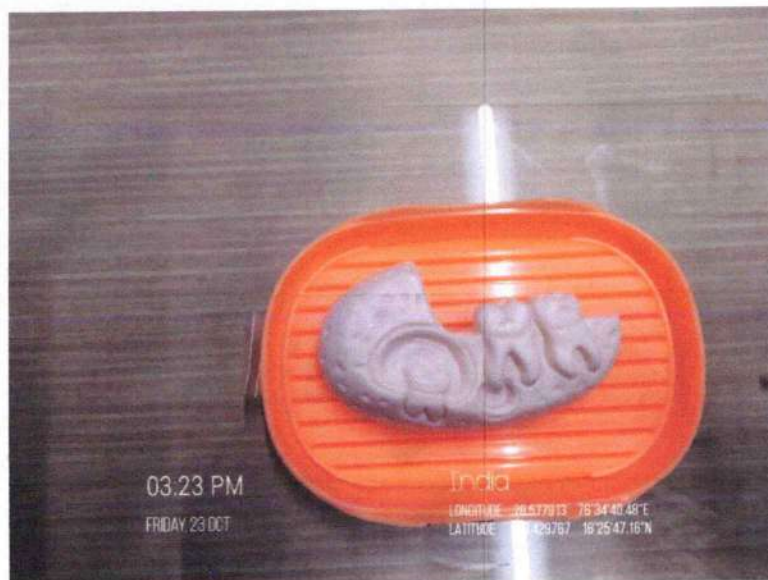
Submitted by Intern Batch 2018 (Oral Pathology department in 2018)



Microscope Wax Model

6) Dentigerous cyst- Soap model


Submitted Rahul B, Shraddha J (Oral Pathology department in 2019)



Dentigerous cyst- Soap model

7) Snake-Ladder Wax Model

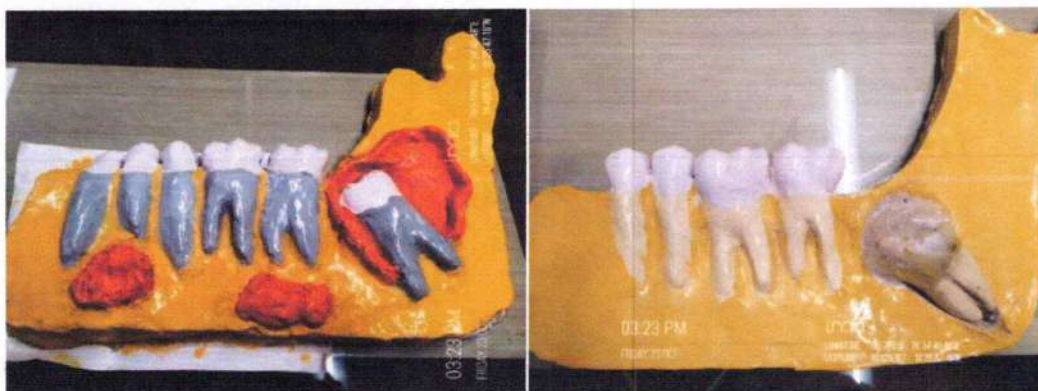
Submitted by Madhuri, Aboli, Akshay, Nishigandha (Oral Pathology department in 2016)



Snake-Ladder Wax Model

8) Cyst-Plaster Models

Submitted by Intern Batch 2016 (Oral Pathology department in 2016)



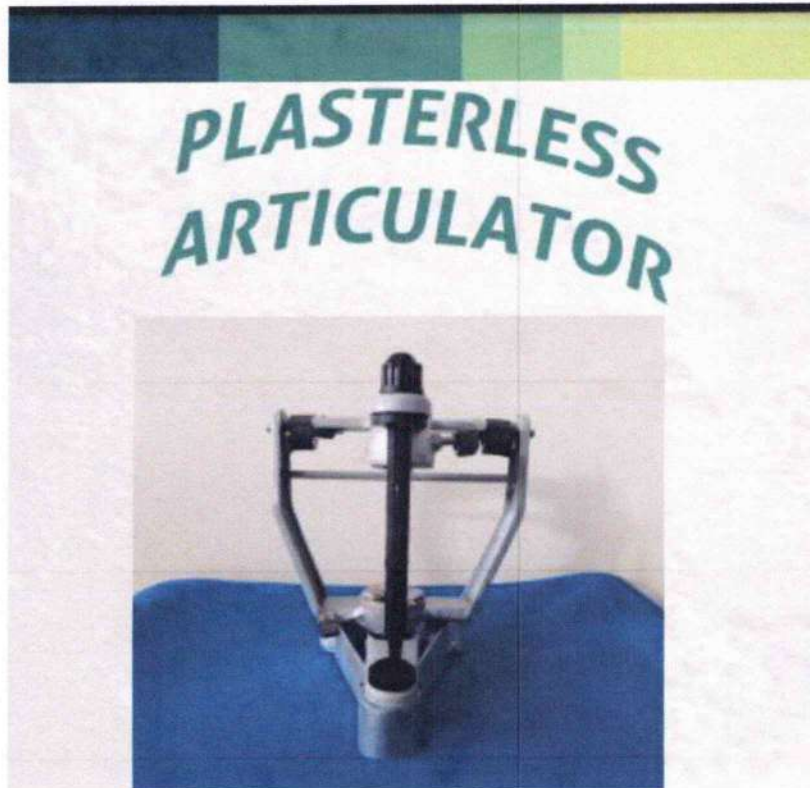
Cyst-Plaster Models

B) Table Clinics

1. PLASTERLESS ARTICULATOR (TABLE CLINIC) –43 IPS CONFERENCE HYDERABAD (06/12/15)

Presented by:

**Dr. Mohammed Asim, Dr. Vidya Gatkal, Dr. Pooja Agroya, Dr. Madhuri
Wadhwani.**



Plasterless Articulator

PLASTERLESS ARTICULATOR

ADVANTAGES OF PLASTERLESS ARTICULATOR

- 1) Plasterless (no untidy work, no effect of setting expansion and time saving)
- 2) No usage of water, therefore less corrosion
- 3) Magnet retained
- 4) Movements – vertical, antero-posterior, lateral
- 5) Diagnosis and treatment planning
- 6) Can be used for multiple cases

LIMITATIONS OF PLASTERLESS ARTICULATOR

- 1) Not a fully adjustable articulator
- 2) Magnetic field may wear off over a period of time

Plasterless Articulator



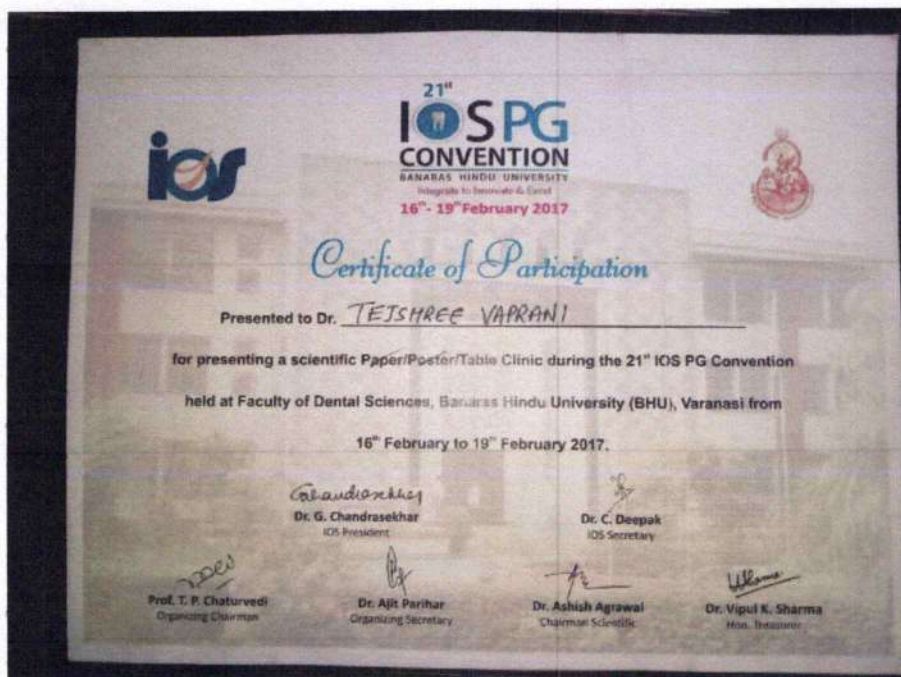Dr. Mohammed Asim, Dr. Vidya Gatkal, Dr. Pooja Agroya, Dr. Madhuri Wadhvani with table clinic

2. Expe-Ortho Table Clinic

Presented by: Dr Tejshree Vaprani at IOS PG Convention, Varanasi on 16th Feb-19th Feb 2017



Expe-Ortho Table Clinic



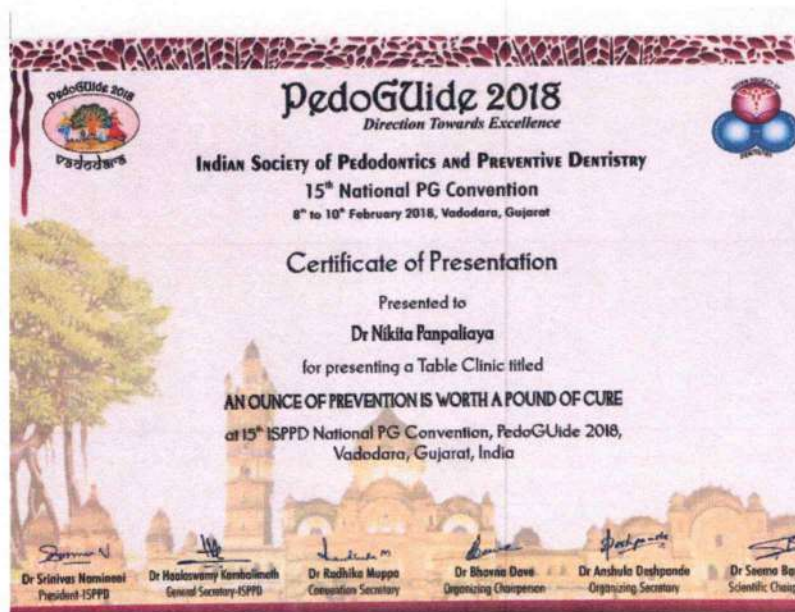Certificate of Expe-Ortho Table Clinic

3. Table Clinic-An ounce of prevention is worth a pound of cure

Presented by: Dr. Nikita Panpaliya at 15th National PG Convention, Vadodara, Gujrat on 8th-10th Feb. 2018



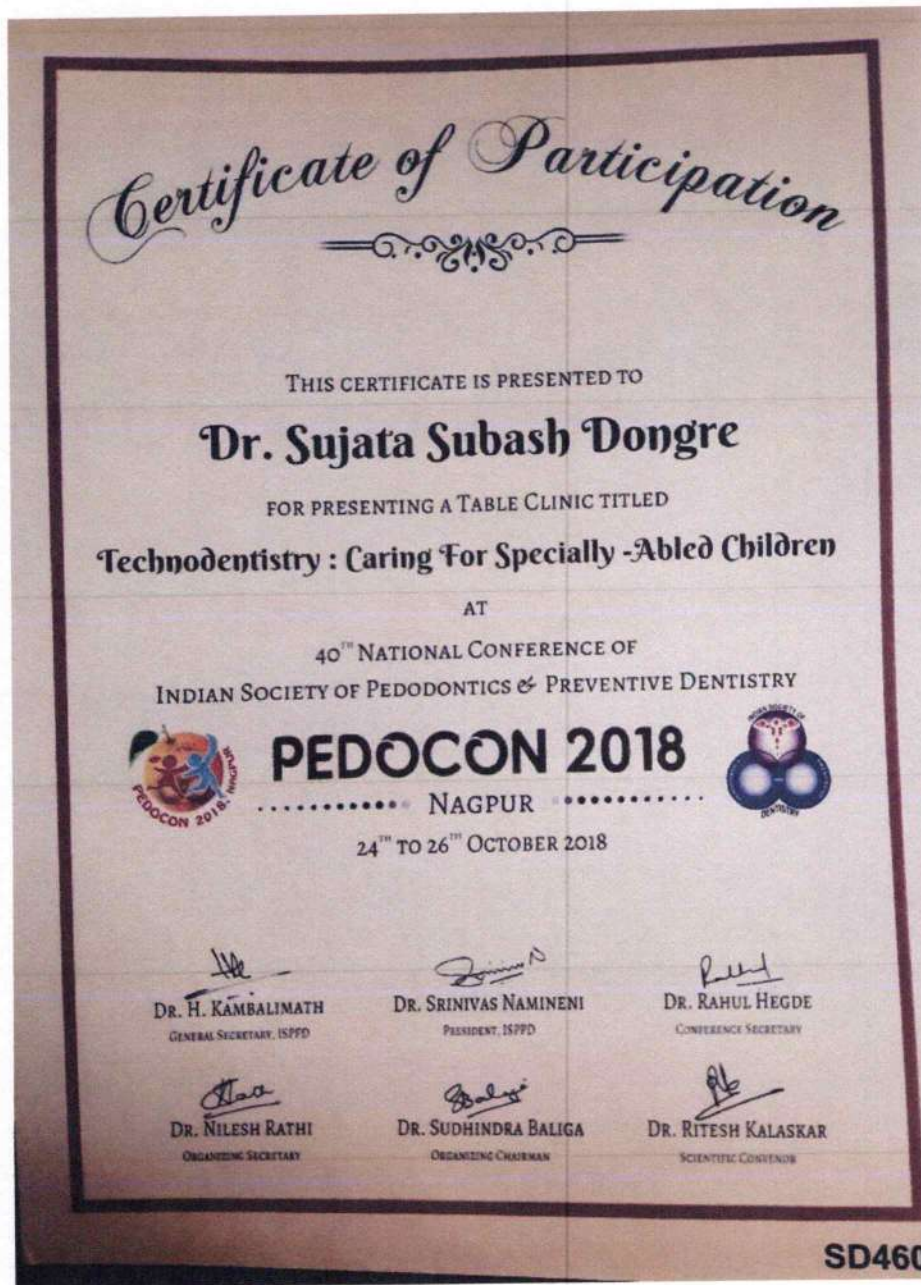Dr. Nikita Panpaliya with Table Clinic An ounce of prevention is worth a pound of cure



Certificate of Table Clinic An ounce of prevention is worth a pound of cure

4. Table Clinic- Technodentistry: Caring for Specially-Abled Children


Presented by: Dr. Sujata Dongre at 40th National Conference of Indian Society of Pedodontics & Preventive Dentistry at Nagpur, on 24th to 26th Oct. 2018



Certificate of Table Clinic Techno dentistry: Caring for Specially-Abled Children

5. Table Clinic- Occlusal Splints: A Simplified approach in Temporomandibular disorder

Presented by- Dr Suraj Sonawane and Dr Deepali Patane at 46th IPS National Conference, Mangalore on 15th-18th Nov. 2018



Dr Suraj Sonawane with Table Clinic



Dr Deepali Patane with Table Clinic



46TH INDIAN PROSTHODONTIC
SOCIETY CONFERENCE
MANGALORE, KARNATAKA, INDIA

CERTIFICATE OF APPRECIATION

Presented to

Dr. Suraj Sunil Sonawane

for presenting table clinic titled

Occlusal splint: A simplified approach in temporomandibular disorder

at 46TH IPS CONFERENCE
held in Mangalore, Karnataka
from 15th to 18th November 2018


Dr. Kashinath K R
President, IPS


Dr. V Rangarajan
Secretary & Treasurer, IPS


Dr. Chethan Hegde
Chairman


Dr. Manoj Shetty
Secretary & Treasurer


Dr. Sanath Shetty
Scientific Chairman



**Certificate of Dr Suraj Sonawane's Table Clinic- Occlusal Splints: A Simplified
approach in Temporomandibular disorder**



46TH INDIAN PROSTHODONTIC
SOCIETY CONFERENCE
MANGALORE, KARNATAKA, INDIA

CERTIFICATE OF APPRECIATION


Presented to


Dr. Deepali Ramling Patane


for presenting table clinic titled


Occlusal splint: A simplified approach in temporomandibular disorder


at 46TH IPS CONFERENCE
held in Mangalore, Karnataka
from 15th to 18th November 2018


Dr. Kashinath K R
President, IPS


Dr. V Rangarajan
Secretary & Treasurer, IPS


Dr. Chethan Hegde
Chairman


Dr. Manoj Shetty
Secretary & Treasurer


Dr. Sanath Shetty
Scientific Chairman



REDEFINING PRECISION

Certificate of Dr Deepali Patane's Table Clinic- Occlusal Splints: A Simplified approach in Temporomandibular disorder

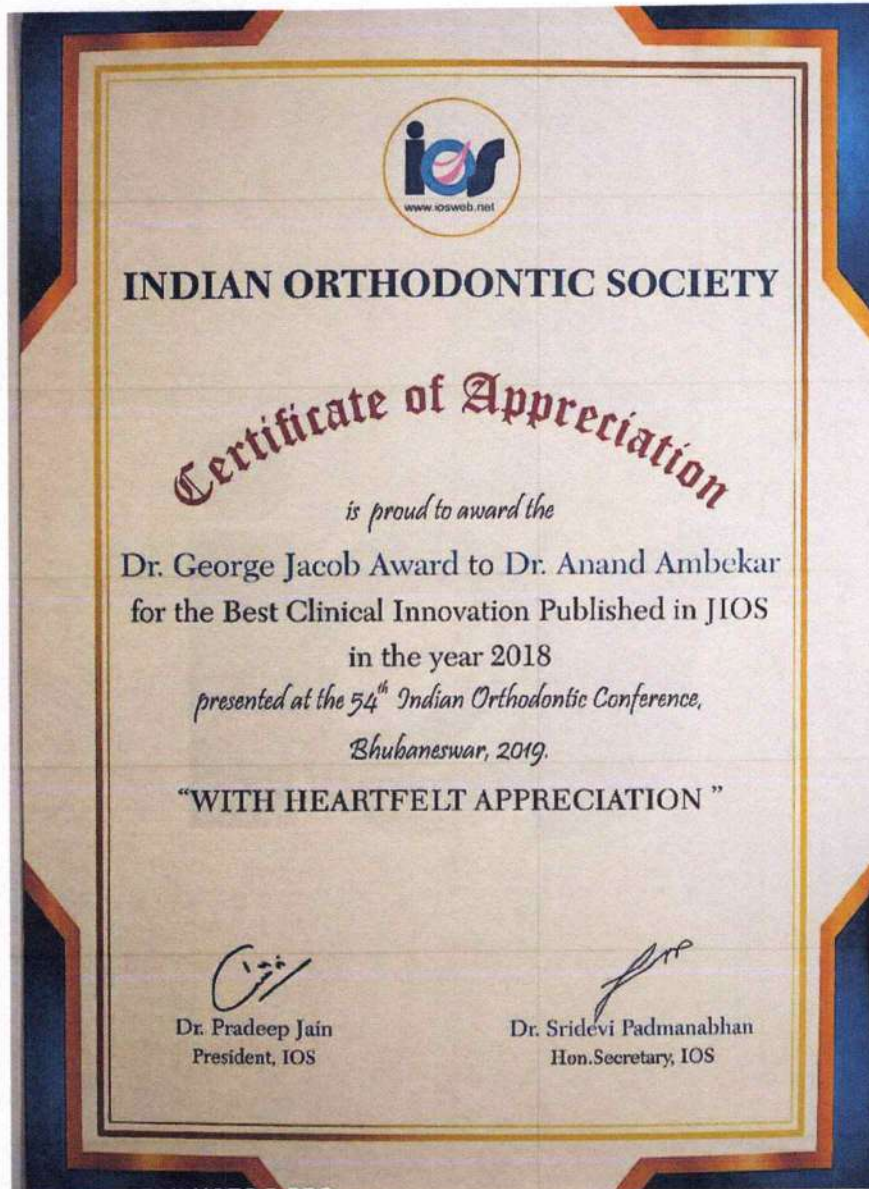
C) Clinical Innovations: 1) A-KAM Bracket Positioning Device

Innovation made by- Dr Anand Ambekar, Dr Khushbu D Agrawal,

Dr Abhidnya Madansure, Dr Manasi Sonawane



Dr Anand Ambekar Receiving George Jacob Award -for the Best Clinical Innovation published in JIOS
2018 in 54th Indian Orthodontic Conference 2019



Certificate of George Jacob Award -for the Best Clinical Innovation published in JIOS 2018 in 54th Indian Orthodontic Conference 2019

2) New Suturing Method for Stabilizing Connective Tissue Grafts at Recipient Sites for Root Coverage and Gingival Augmentation

Innovation made by- Dr Om Nemichand Baghele (2019)

Original Research

A Detailed Description and 16-Year Validation of a New Suturing Method for Stabilizing Connective Tissue Grafts at Recipient Sites for Root Coverage and Gingival Augmentation

Abstract

Background: Which are the different ways of stabilizing connective tissue grafts (CTGs) for root coverage and gingival augmentation by means of placement of sutures? There are various defined and undefined ways of stabilizing CTGs depending on experience and personal preferences. Most of the techniques profess use of absorbable sutures in separate interrupted fashion (sutures at the corners of the graft wherever possible). **Aim:** This paper describes a new suturing method, "the lingually-tied horizontal mattress contouring suture," for stabilization of CTGs with or without epithelialized collar at the recipient site, for use with papilla retention and sparing techniques to treat marginal tissue recessions. **Methods and Material:** The suturing technique is described in detail. It can be indicated for good number of root coverage cases, with additional objectives of gingival augmentation, specifically developed for papilla sparing and papillary buccal de-epithelialization recipient site preparations. **Results:** Over a period of last 16 years this suturing technique showed promising results in terms of graft stabilization and survival. The main advantage of this technique lies in the use of cost-effective nonabsorbable sutures that usually retain some amount of tension on the soft tissues longer. **Conclusion:** The primary objective of the suturing technique, *per se*, is to stabilize the CTG firmly along the contours of the root surface and to expedite a very close adaptation to the interdental soft tissues as well. The secondary objective of the article or publication is to disseminate the knowledge acquired through long periods of performance and observation for the benefit of the periodontal community as whole. Further validation is advocated.

Keywords: Connective tissue grafting, gingival augmentation, graft stabilization, root coverage, periodontal plastic surgery, new suturing technique, non-absorbable sutures

Introduction

As of today, a vast variety of root coverage techniques are available at a clinician's disposal, along with many specified and unspecified suturing techniques. Most of the suturing techniques employed for free or pedicled connective tissue grafts (CTGs) use absorbable sutures, at least for securing and stabilizing the graft. The overlying gingival/mucosal tissue is then approximated with either absorbable or nonabsorbable sutures. Close adaptation to underlying vascular recipient bed and under-surface of overlying flap can be achieved most of the times with enough number and appropriate location of sutures; a snugly fitting close contoured adaptation of free CTG with or without epithelialized collar (CTG-consider this abbreviation for brevity of description throughout this manuscript) over the convex root surface may be at times lacking.

This is an open access journal, and articles are distributed under the terms of the Creative Commons Attribution-NonCommercial-ShareAlike 4.0 license, which allows others to remix, tweak, and build upon the work non-commercially, as long as appropriate credit is given and the new creations are licensed under the identical terms.

For reprints contact: reprints@medknow.com

Even though the decision to place sutures at surgically wounded periodontal tissues may be influenced by the type of procedure, extent of procedure, tissues involved and arrangement of tissue fibers, patient and operator factors and intended results; one of the best ways of stabilizing the tissues is to anchor them with the adjacent tooth/teeth. Suture placements, although may not be mandatory always, are generally intended to maximize the opportunity for uneventful healing, minimize the likelihood of infection, approximation of wound with as little trauma as possible, and providing appropriate tension for requisite periods of time.

With the increasing use of 4-0 and small diameter sutures, may or may not be aided by loupes and microscopes, the suturing techniques have become more complex and tedious, although more dependable too in terms of wound healing. Rather than the increasing complexities and

How to cite this article: Baghele ON. A detailed description and 16-year validation of a new suturing method for stabilizing connective tissue grafts at recipient sites for root coverage and gingival augmentation. *Indian J Dent Res* 2019;30:243-8.

Om Nemichand Baghele

Professor, Department of Periodontology, Maharashtra Institute of Dental Sciences and Research, Latur, Maharashtra, India

Address for correspondence:

Dr. Om Nemichand Baghele, Department of Periodontology, Maharashtra Institute of Dental Sciences and Research, Ambajogai Road, Vishwanathpuram, Latur - 413 512, Maharashtra, India.
E-mail: drom94@yahoo.com

Access this article online

Website: www.ijdr.in

DOI: 10.4103/ijdr.IJDR_614_17

Quick Response Code:



manoeuvrability, techniques should be simple to understand, easy to perform, requiring less specialized equipment and still predictable in achieving intended success.

This paper illustrates a suturing technique for stabilizing the CTG to a contoured root surface in a predictable way, using nonabsorbable sutures and performed without the use of any magnifying aids. The unique features involved are starting at a lingual purchase point, starting from fixed tissue rather than free tissue margins, and tying at the lingual side or slightly in the linguo-gingival embrasure area. The author is using this technique since 2001, which was described then for the first time in his dissertation.^[1] Subsequently, the technique was mentioned briefly in a 2012 publication.^[2] The technique in entirety was never published, that is why it is described in detail in this article. One of the objectives is to disseminate this unique technique of suturing for everybody's benefit.

Methods

Suturing technique

This suturing technique makes use of the internal horizontal mattress type of suturing and also sling-like configuration that is continuous for two adjacent retained papillae. The retained papillae and the CTG are sutured together to secure in a coronal-apical direction and then the whole unit is stabilized with tooth as anchoring unit. If there are more than two adjacent teeth selected for root coverage, appropriate numbers of such sutures are required to be placed. For single tooth root coverage procedure, there is no confusion for selecting the anchor tooth. For three adjacent teeth simultaneous root coverage procedure, select the terminal teeth as anchors. For two adjacent teeth either both teeth can be selected as anchors with the same suturing technique followed, the centrally located papilla will have four piercings, or either one of them can be

selected as anchor tooth and after the contoured suturing technique, a single lingually tied horizontal mattress suture placed with the remaining single retained papilla.

Although this technique is specifically developed for use of nonabsorbable sutures, the use of absorbable sutures is not a contraindication. Depending on the comfort levels of the clinician, a 4-0, 5-0, or 6-0 suture can be used. A small to medium head needle holder or microsurgical Castroviejo needle holder is appropriate for handling the suture needle. Again, needle holders can be selected as per the experience of the clinician. Although the starting point for this suturing technique can be any one of the retained papilla, it is easier to start at the mesial side, where it is easier to tie the knot as well.

Technique involves following steps [Figures 1-3]

Step 1 – Choose any one of the retained papilla, preferably mesially located. Starting from the lingual side, insert suture needle in the middle (slightly off-center) and at the base of the interdental papilla. If you are following Bruno's technique,^[3] then it should be corresponding to the first horizontal incision given on the buccal side for intended butt joint (the needle should come out at or slightly apical to the horizontal incision). Pass the needle from the lingual side to buccal side [Figure 1].

Step 2 – Keeping the graft in place and holding it with an appropriate Corn's suture pliers, pass the needle from the lingual side of the graft to exit it from the buccal side. Keep at least around 1.5 mm of bite from the coronal margin of the CTG. For Bruno's technique, go for a butt joint, whereas for papillary de-epithelialization technique, one can adjust the coronal location of CTG margin as per the requirement. If you want to place the margin more coronally take a deeper (more) bite [Figures 1 and 2].

Step 3 – Make around 3–4 mm of horizontal mattress on the buccal side of graft, and again holding it with suture

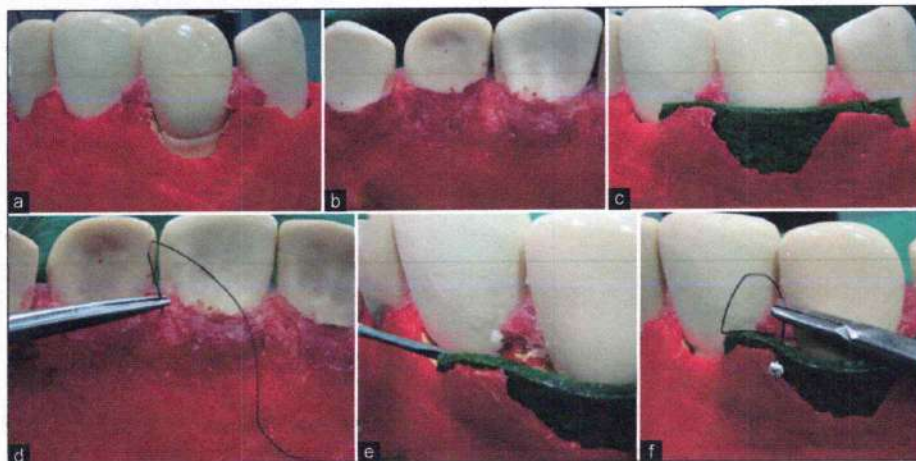


Figure 1: The lingually tied horizontal mattress contouring suture (Panel 1). (a) Recession on canine with horizontal papilla sparing incisions (Bruno's technique). (b) View from lingual side. (c) Placement of connective tissue grafts with/without epithelialized collar (green). (d) Starting the suturing from lingual side. (e) Needle coming out (white stopper in all photographs) from buccal side just at the base of retained papilla. (f) Piercing the connective tissue grafts from lingual aspect to buccal

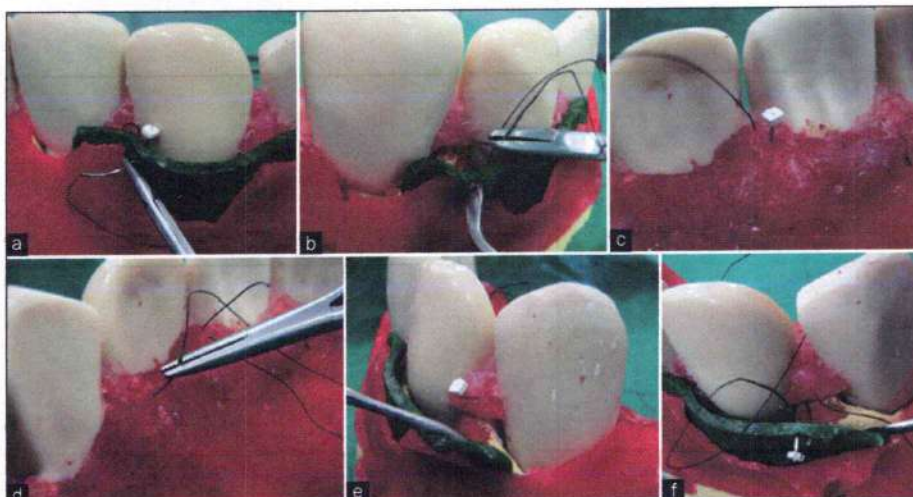


Figure 2: The lingually tied horizontal mattress contouring suture (Panel 2). (a) Piercing the connective tissue grafts from buccal aspect to lingual. (b) Advancing the needle through buccal aspect of retained papilla to lingual side. (c) Needle coming out from lingual side. (d) Crossing over to the other retained papilla, piercing from its lingual aspect. (e) Needle coming out on buccal side. (f) Piercing the connective tissue grafts from lingual aspect to buccal

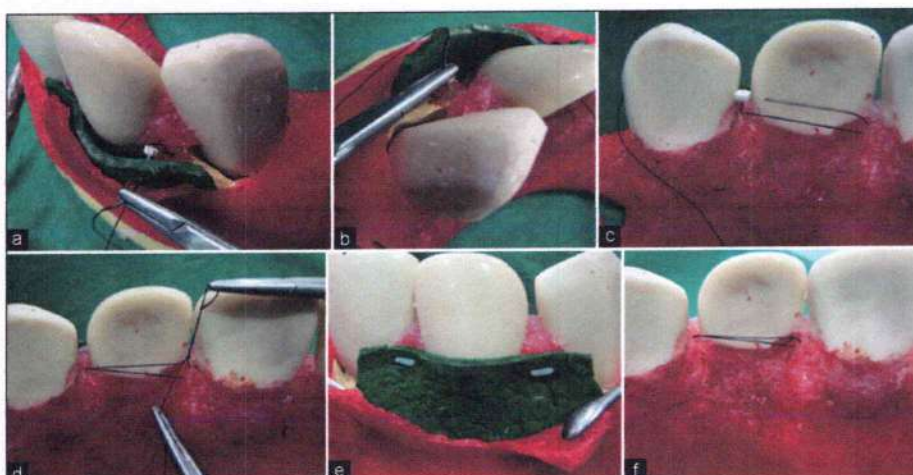


Figure 3: The lingually tied horizontal mattress contouring suture (Panel 3). (a) Piercing the connective tissue grafts from buccal aspect to lingual. (b) Advancing the needle through buccal aspect of this retained papilla to lingual side. (c) Needle coming out from lingual side. (d) After adjusting the whole suture complex with appropriate tension, tie the knot on lingual side. (e) The stabilized connective tissue grafts. Look at the horizontal mattress marked with white. (f) Postoperative lingual side

pliers pass the needle from buccal side to lingual, keeping the bite similar as in the step 2.

Step 4 – Now pass the needle through the retained interdental papilla. Insert the needle from the buccal side just at the first horizontal incision, in case of Bruno's technique, and exit it from the lingual side, as per requirement in other techniques (other than Bruno's) [Figure 2].

Step 5 – Pull an appropriate amount of suture on the lingual side, keeping enough tie arm and applying a light tension on the buccal mattress adjust the positioning of the graft.

Step 6 – Pass the suture needle through adjacent retained interdental papilla of the same tooth, crossing the lingual surface of the anchor tooth. Starting from the lingual side again, repeat all the steps from 1 to 4 [Figures 2 and 3].

Step 7 – By applying some adjusting tension (gentle pull) on the tag and tie arms of the suture, the graft is stabilized in place as per the convexity of the root surface. The graft gets snugly adapted to the contour of the root/tooth. Sometimes there is lifting of the graft from apical end, while tying the suture placed. A simple measure of applying finger pressure may or may not be accompanied by moist saline gauze, for 1–2 minutes adapts the whole graft properly. The act of applying pressure eliminates the dead space and accumulated blood and fluid, and usually there is some weak adhesion between the undersurface of CTG and retained connective tissue base or bone surface.

Step 8 – The suture is finally tied on the lingual side with appropriate knot anatomy. Keep the cut ends toward the interdental area [Figure 3].

Step 9 – At this point, additional sutures for graft stabilization can be considered, if you are covering more than one tooth as mentioned earlier.

Step 10 – There is no need to put any suture at the apical and lateral margins of the CTG.

Step 11 – Now you can go ahead with suturing the overlying gingival/mucosal tissue. One can follow any one of their preferred techniques. Cross and parallel suspensory sutures can be utilized, additionally composite sutures penetrating the overlying flap, the CTG and the retained papilla can be considered. As far as possible, aim for complete coverage of the graft by the overlying flap.

Contoured graft stabilization

As this technique applies gentle pull from both the ends of the suture across the curvature of the root, the graft stabilizes in a contoured fashion with the best achievable contact between recipient bed and the graft [Figure 4]. With no immediate loss of suture tension, due to use of nonabsorbable sutures and less ensuing inflammation too, the intimate adaptation may promote early and faster

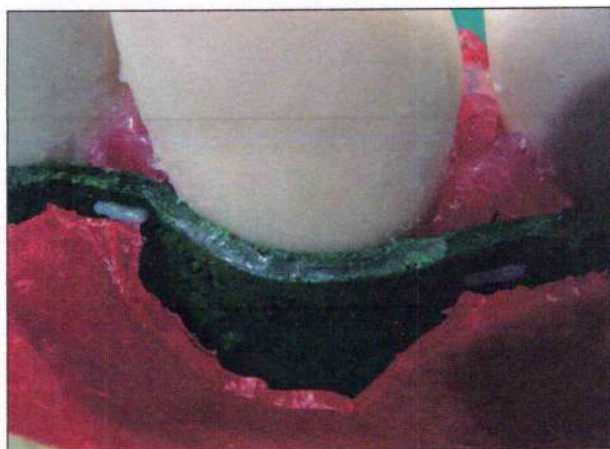

Figure 4: Snugly fitting close contoured adaptation of the connective tissue grafts

healing. Because of the solid anchoring unit, the tooth, natural tooth movements during function will translate to periodontal ligament only, rather than movements between the graft and the tooth. The mattress parts at the interdental sites also ensure an intimate contact with the retained tissues and vascular bed and may act as a preventive mechanism for formation of seromas and hematomas. The postoperative wound distraction forces, mastication, deglutition, speaking, brushing, laughing, etc., should not be able to displace the immobilized graft for a sufficient period of time postsurgery.

Key surgical points

- i. We should not be overly concerned about the principles of suturing, mentioning starting suture placements from the loose or elevated tissue to fixed tissue. That is one of the principles of suturing, which is modified here for our advantage
- ii. Lingually tied sutures may irritate the tongue, but within no time the cut ends will settle in the interdental space
- iii. While tying the knot, just enough tension is applied so as to get a close contoured adaptation. Excessive tension may jeopardize the graft, whereas less tension may cause movement and may not lead to contoured adaptation
- iv. Preferably use a nonresorbable suture material with atraumatic swaged needle. Different suture materials that can be used for this technique are mentioned in Table 1
- v. Use of digital pressure on graft is advisable to enhance adaptation by eliminating dead space and accumulated blood and fluid
- vi. As the knot is on the lingual side, it is much away from the wound edges, which is preferable
- vii. For beginners, practising on the models, as illustrated in this article, will help immensely

Few clinical cases are represented in Figure 5. The posthealing photographs of the same cases are shown in Figure 6.

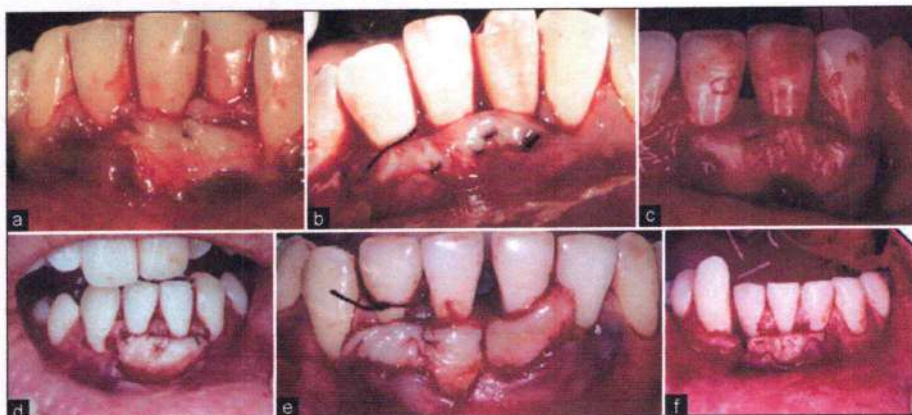


Figure 5: Clinical photographs of six different cases

Table 1: Different suture materials which can be used for the suture technique explained

Material	Nature	Preferable diameters	Comments
Silk, surgical	Nonabsorbable, natural	4-0, 5-0	Twisted or braided silk have tendency for plaque/bacterial accumulation (wicking)
Nylon, polyamide	Nonabsorbable, synthetic	4-0, 5-0	Monofilament polyamide has tendency for knot loosening and if cut ends are kept on the lingual side, there are chances of tongue injury because the cut ends remains stiff and sharp. If you are considering using polyamine use a periodontal dressing only on the lingual side
Polypropylene	Nonabsorbable, synthetic	4-0, 5-0	Nylon, polypropylene and ePTFE sutures have less tissue reactions than silk
ePTFE/PTFE	Nonabsorbable, synthetic	4-0	The tissue reactions are more pronounced as compared to nonabsorbable
Plain or chromic gut	Absorbable, natural	4-0, 5-0	Synthetic absorbables show less tissue reactions to natural absorbables
Coated or uncoated polyglactin 910	Absorbable, synthetic	4-0, 5-0	Absorption process may start prematurely, owing to contact between oral fluids and blood
			As surgical oral and periodontal wounds are clean-contaminated wounds, presence of infection or inflammatory oedema may enhance absorption of sutures
			The process of absorption may be varied and unpredictable for each individual
			Braided or monofilament polyglactin 910 sutures show minimal to moderate acute inflammatory reaction

Notes: Diameters are written as per author's preference when the surgery is done without the aid of any magnification paraphernalia

Author's preference is for nonabsorbables, as the technique described is preferably for the same

The most costeffective sutures are silk sutures

ePTFE=Expanded-polytetrafluoroethylene

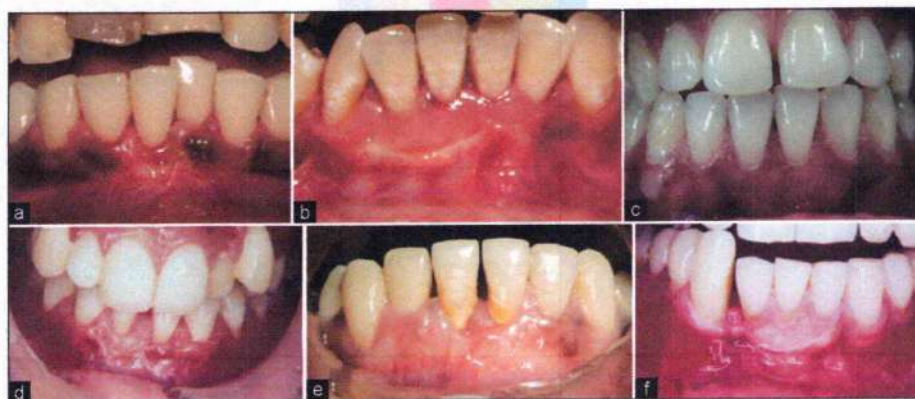

Figure 6: Posthealing (10 months to 14 years) photographs of patients shown in Figure 5

Discussion

Basically the suturing technique described in this paper is for nonabsorbable suture material. Ideally, the choice of the suture material should be based on the biological interaction of the materials employed, the tissue configuration, and the biomechanical properties of the wound. The tissue should be held in apposition until the tensile strength of the wound is sufficient to withstand stress.^[4]

The rate at which wounds, whether surgical or accidental, regain strength during the healing process should also be considered for selecting appropriate suture material.

Skin^[5] and mucosa regain tensile strength slowly during healing. One of the optimal suture qualities include, not only presence of high uniform tensile strength but also its retention *in vivo*, holding the wound securely throughout the critical healing period, followed by rapid absorption.^[5] There is undoubtedly availability of good absorbable suture materials today, but to err on the side of caution, the author suggests nonabsorbable sutures. The degradation of absorbable sutures, either by enzymatic dissolution or hydrolysis, starts from the first contact of the suture materials to that of body fluids and tissues. This may lead to some amount of loss in tension. Moreover, it

has been found that the absorbable sutures lead to more amount of acute inflammatory reaction as opposed to some nonabsorbable suture materials.^[5] This acute host reaction again may lead to some loss in tension. Still, it is advisable to clinicians to stick to their preferred suture material for stabilizing the CTG, whether it is absorbable or nonabsorbable.

In his original description, Bruno^[3] secured the CTG at recipient site with interrupted sutures utilizing 6-0 monofilament pliability nylon with a (PC-3) conventional cutting needle. Langer and Calagna^[6] mentioned that "the recipient flap is coapted over most of the graft and sutured in place in a manner which will immobilize the underlying graft." That means, the CTG and the overlying flap were sutured together. Langer and Langer^[7] following similar technique used either 4-0 silk and CE-2 atraumatic needle or chromic gut with a CE-2 atraumatic needle.

Harris^[8] recommended suturing of CTG into the recipient site with 5-0 gut sutures at the corners of the graft ensuring good contact of the graft with the bed. Carvalho *et al.*^[9] utilized 5-0 polyglactin 910 vicryl sutures in a sling suture fashion to stabilize the CTGs. Most of the other techniques utilize absorbable sutures, most commonly in the configuration of 4-0, 5-0, or 6-0, in an interrupted single suture conventional manner. If one is doing grafting procedure without any magnification aid, it is comfortable to use 4-0 or 5-0 sutures. A 3/8 circle or half circle reverse cutting or round bodied swaged atraumatic suture needle should be considered as per the clinicians comfort. Since 2001, the author is using this technique with not a single loss of grafted tissue, so personal validation is now for >16 years.

Conclusion

The "lingually tied horizontal mattress contouring suture," when appropriately done as described in this paper, will be an asset to a clinician's repertoire. It obviates any need for using resorbable sutures for stabilizing CTGs for root coverage or gingival

augmentation. It is cost effective as well as a simplistic suturing technique. Further validation from clinicians across the world is warranted. Wound closure promoting optimum healing in minimum time should be the goal of most surgical procedures and it looks as if the described suture technique may not be in disagreement with the stated goal.

Financial support and sponsorship

Nil.

Conflicts of interest

There are no conflicts of interest.

References

1. Baghele ON, Pol DG. An Evaluation of the Effectiveness and Predictability of Transpositional Flap Versus Connective Tissue Graft for Coverage of Miller's Class-I and Class-II Facial Gingival Recession Lesions – A Clinical Study. Dissertation Submitted to the Mumbai University, Mumbai, India; 2002.
2. Baghele ON, Pol DG. An evaluation of the effectiveness and predictability of transpositional flap vs. connective tissue graft for coverage of Miller's class-I and class-II facial marginal tissue recession lesions: A clinical study. *Indian J Dent Res* 2012;23:195-202.
3. Bruno JF. Connective tissue graft technique assuring wide root coverage. *Int J Periodontics Restorative Dent* 1994;14:126-37.
4. Edlich RF, Long WB. *Surgical Knot Tying Manual*. 3rd ed. Norwalk, CT: Covidien AG; 2008.
5. Dunn DL. *Wound Closure Manual*. Somerville, NJ: Ethicon Inc., Johnson & Johnson; 2005.
6. Langer B, Calagna LJ. The subepithelial connective tissue graft. A new approach to the enhancement of anterior cosmetics. *Int J Periodontics Restorative Dent* 1982;2:22-33.
7. Langer B, Langer L. Subepithelial connective tissue graft technique for root coverage. *J Periodontol* 1985;56:715-20.
8. Harris RJ. Double pedicle flap – Predictability and aesthetics using connective tissue. *Periodontol* 2000 1996;11:39-48.
9. Carvalho PF, da Silva RC, Cury PR, Joly JC. Modified coronally advanced flap associated with a subepithelial connective tissue graft for the treatment of adjacent multiple gingival recessions. *J Periodontol* 2006;77:1901-6.

3) Classification Of Orthodontic Practice In India

Innovation made by- Dr Yatishkumar Joshi

  Extracts
from the Register
of Copyrights

Dated : 22/05/2019

1. Registration Number	: L-82671/2019
2. Name, address and nationality of the applicant	: YATISH KUMAR JOSHI, IDEAL DENTAL CARE, PRAISHU COMPLEX BASEMENT, OPP. GARAD GARDEN, BARSHI ROAD, LATUR, MAHARASHTRA, INDIA-413512INDIAN
3. Nature of the applicant's interest in the copyright of the work	: AUTHOR
4. Class and description of the work	: LITERARY/ DRAMATIC WORK
5. Title of the work	: CLASSIFICATION OF ORTHODONTIC PRACTICE IN INDIA
6. Language of the work	: ENGLISH
7. Name, address and nationality of the author and if the author is deceased, date of his decease	: YATISHKUMAR JOSHI, IDEAL DENTAL CARE, PRAISHU COMPLEX BASEMENT, OPP. GARAD GARDEN, BARSHI ROAD, LATUR, MAHARASHTRA, INDIA-413512INDIAN
8. Whether the work is published or unpublished	: UNPUBLISHED
9. Year and country of first publication and name, address and nationality of the publisher	: N.A.
10. Years and countries of subsequent publications, if any, and names, addresses and nationalities of the publishers	: N.A.
11. Names, addresses and nationalities of the owners of various rights comprising the copyright in the work and the extent of rights held by each, together with particulars of assignments and licences, if any	: YATISHKUMAR JOSHI, IDEAL DENTAL CARE, PRAISHU COMPLEX BASEMENT, OPP. GARAD GARDEN, BARSHI ROAD, LATUR, MAHARASHTRA, INDIA-413512INDIAN
12. Names, addresses and nationalities of other persons, if any, authorized to assign or license rights comprising the copyright	: N.A.
13. If the work is an 'Artistic work', the location of the original work, including name, address and nationality of the person in possession of the work. (In the case of an architectural work, the year of completion of the work should also be shown).	: N.A.
14. If the work is an 'Artistic work' which is used or capable of being used in relation to any goods or services, the application should include a certification from the Registrar of Trade Marks in terms of the provisions to Sub-Section (3) of Section 45 of the Copyright Act, 1957.	: N.A.
15. If the work is an 'Artistic work', whether it is registered under the Designs Act 2000 if yes give details.	: N.A.
16. If the work is an 'Artistic work', capable of being registered as a design under the Designs Act 2000, whether it has been applied to an article through an industrial process and, if yes, the number of times it is reproduced.	: N.A.
17. Remarks, if any	

Dary Number : 4528/2019-COVL
Date of Application : 01/04/2019
Date of Receipt : 01/04/2019

 
DEPUTY REGISTRAR OF COPYRIGHTS

Copyright for Classification Of Orthodontic Practice In India


Principal
M.I.D.S.R. Dental College
LATUR